



**PATIENT**

Ruzi Hodjat

**RESENTING CLINICAL SIGNS**

History: New grade 1-2/6 soft, systolic heart murmur. Asymptomatic.  
Abnormal PE/Chem/CBC/UA Results: Elevated ALKP 1688 (chronic but increasing), normal thyroid and CBC/chem panel/electrolytes. Patient is over-conditioned.

**SPECIES**

Canine

**ECHOCARDIOGRAM FINDINGS**

2D, m-mode, color flow and doppler imaging is available. Mild mitral valve leaflet thickening with no obvious prolapse into the left atrial lumen. No mitral regurgitation is identified. Normal left atrial dimension. Normal LV diameter with normal myocardial function. The tricuspid valve appears subjectively normal. Trivial TR. Normal velocity. The right heart is normal. No overt evidence of pulmonary arterial hypertension. The pulmonic and aortic valves are normal in morphology and mobility. No aortic abnormalities identified, with normal outflow velocity. Normal pulmonic outflow velocities. No aortic insufficiency. No pulmonic insufficiency. No pericardial or pleural effusion noted. No cardiac tumors observed.

**BREED**

Lab/Dalmation Mix

**SEX**

Female Spayed

**CARDIAC CHART**

**AGE**

11.4 years

CANINE CARDIAC PARAMETERS	MR VMAX (m/s)	TR VMAX (m/s)	LA/AO (Boon method)	LA/AO (Heart Base; Swe)	FS (%)	EF (%)	EPSS (cm)
<b>NORMAL PARAMETER</b>	4.5-5.5	<2.7	1.3	<1.6	28-40	40-100	<0.6
<b>PATIENT</b>	NA	2.0	NM	1.3	43	80	049
CANINE CARDIAC PARAMETERS	HR (BPM)	AV VMAX (m/s)	PV MAX (m/s)	BODY WEIGHT (kg)	LA 2D short axis Base view (cm)	LVIDd Avg; 2D and m-mode short axis (cm)	LVIDs Avg; 2D and m-mode short axis (cm)
<b>NORMAL PARAMETER</b>	50-100	0.7-1.7	0.7-1.6	BELOW	BELOW	BELOW	BELOW
<b>PATIENT</b>	NM	1.3	1.5	27.7	2.4	2.8	1.6
*Normal chamber parameters expressed as a mean value (SD)				3	1.27 (5.3)	2.46 (2.46)	1.36 (5.5)
<b>BODY WEIGHT DEPENDENT PARAMETERS</b>				5	1.40 (4.5)	2.74 (5.2)	1.60 (4.7)
<i>*Note: All measurements based upon multi-modal images and methods. An average value is reported.</i>				10	1.50 (3.8)	3.27 (3.5)	2.06 (3.1)
				15	1.83 (2.0)	3.71 (2.4)	2.43 (2.1)
				20	2.02 (1.9)	4.14 (2.2)	2.80 (2.0)
				25	2.18 (2.4)	4.48 (2.9)	3.10 (2.5)
				30	2.33 (3.3)	4.83 (3.9)	3.39 (3.4)
				35	2.48 (4.3)	5.17 (5.0)	3.69 (4.5)
				40	2.62 (5.2)	5.48 (6.1)	3.96 (5.4)
				50	2.88 (7.1)	6.07 (8.3)	4.46 (7.4)

**INTERPRETATION OF THE FINDINGS & FURTHER RECOMMENDATIONS**

Overtly normal cardiac structure and function with no cause of a murmur identified. No significant valvular insufficiencies were noted, and no structural issues identified. In the absence of significant volume changes (dehydration) or anemia, other possibilities include a physiologic flow murmur only present with elevated heart rates, or a small flow abnormality not seen here. It is reasonable to monitor periodically via recheck echocardiography in the future, particularly should the murmur persist/progress. It is worth noting that this patient is over-conditioned which can limit image clarity.

**INTERPRETED BY**

Maggie Machen Lamy, DVM, DACVIM (Cardiology)

**IMAGING PERFORMED BY**

Amy Mayhew, LVT

**HOSPITAL NAME**

SVS Imaging MI

**REFERRING VET**

Dr. Gut

**INVOICE**

28792

**DATE**

2/6/23

**IMAGING PERFORMED BY**

svsmobileimaging.com 309 - 737 - 3070



**Clinical Sonography & Telecytology**

EDUCATIONAL TELECONSULTATION SERVICES™

1-800-838-4268 info@sonopath.com SonoPath.com

**PATIENT**

Ruzi Hodjat

No cardiac medications are indicated at this time. Monitor for any development of cough, labored breathing or exercise intolerance.

No cardiac contraindication for general anesthesia.

**SPECIES**

Canine

Recommend recheck echocardiogram in 12-18 months to screen for progression or development of concurrent cardiac disease that the preexisting murmur may mask.

**BREED**

Lab/Dalmation Mix

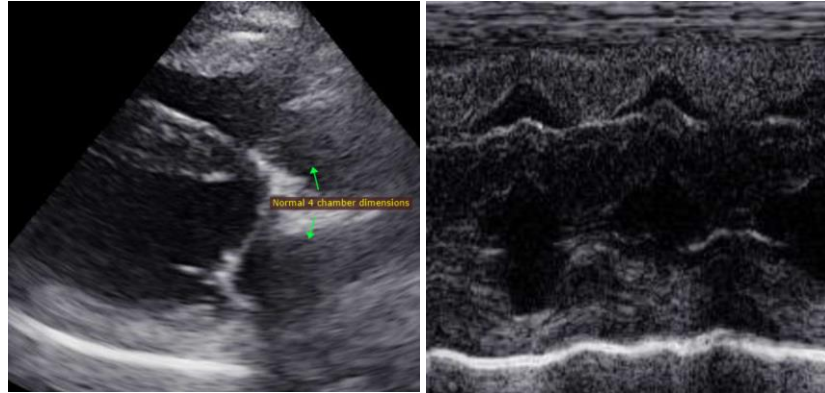
**SEX**

Female Spayed

**AGE**

11.4 years

**IMAGES**



**WEIGHT**

61lbs

**The information and recommendations provided are based on the images presented by the referring veterinarian. No evaluation can be communicated regarding pathology that was not visible in the image/video clips provided.**

**INTERPRETED BY**

Maggie Machen Lamy,  
DVM, DACVIM  
(Cardiology)

Thank you for this referral. If the clinical or image interpretation does not parallel your findings or if I can be of any further assistance, please contact me.

**Maggie Machen Lamy, DVM**  
**Diplomate of the American College of Veterinary Internal Medicine (Cardiology)**  
info@sonopath.com

**IMAGING PERFORMED BY**

Amy Mayhew, LVT

**HOSPITAL NAME**

SVS Imaging MI

**REFERRING VET**

Dr. Gut

**INVOICE**

28792

**DATE**

2/6/23